

## Rara coexistencia de dextrocardia y un quiste aracnoideo de la fosa posterior en un solo caso clínico

Muchtar Nora Ismail Siregar<sup>1,2,\*</sup>, Vickry H Wahidji<sup>1,2</sup>, Muhammad Isman Jusuf<sup>2,3</sup> and Zuhriana K Yusuf<sup>4</sup>

### Resumen

**Antecedentes:** La dextrocardia es una anomalía congénita poco frecuente, observada en aproximadamente 1 de cada 12.000 nacimientos, caracterizada por una posición anómala del corazón y considerada consecuencia de alteraciones tempranas en el desarrollo cardíaco. Este reporte presenta la inusual coexistencia de dextrocardia y un quiste aracnoideo de la fosa posterior, una combinación rara vez descrita. **Resumen del caso:** Una mujer de 25 años consultó por disnea de esfuerzo, ortopnea, disnea paroxística nocturna, fatiga y edema periférico bilateral. El examen físico mostró presión venosa yugular elevada, taquicardia, soplo sistólico, ascitis y edema en las extremidades inferiores. La radiografía de tórax evidenció dextrocardia y cardiomegalia, mientras que la tomografía computarizada cerebral identificó un quiste aracnoideo. Los análisis de laboratorio demostraron anemia leve con función renal y proteínas séricas normales. Se diagnosticó insuficiencia cardiaca congestiva, se inició tratamiento médico y la paciente optó por seguimiento ambulatorio del quiste sin más intervenciones.

**Discusión:** La coexistencia de dextrocardia y un quiste aracnoideo sugiere un posible vínculo genético y respalda la realización de una evaluación genética completa en pacientes con anomalías congénitas. El reconocimiento de estas asociaciones puede mejorar la comprensión de los mecanismos del desarrollo subyacentes y ayudar a afinar las estrategias diagnósticas y de manejo.

*Insuf Card* 2025;20 (1): 24–28.

**Palabras clave:** dextrocardia, quiste aracnoideo, genética, reporte de caso

### Summary

#### *Rare coexistence of dextrocardia and a posterior fossa arachnoid cyst in a single patient case report*

**Background:** Dextrocardia is a rare congenital anomaly, seen in about 1 in 12,000 births, characterized by abnormal cardiac position and thought to result from early cardiac developmental disturbances. This report presents the unusual coexistence of dextrocardia and a posterior fossa arachnoid cyst, a combination seldom described. **Case summary:** A 25-year-old woman presented with exertional dyspnea, orthopnea, paroxysmal nocturnal dyspnea, fatigue, and bilateral peripheral edema. Examination revealed elevated jugular venous pressure, tachycardia, a systolic murmur, ascites, and lower limb edema. Chest X-ray showed dextrocardia and cardiomegaly, while brain CT identified an arachnoid cyst. Laboratory tests demonstrated mild anemia with normal renal function and serum proteins. She was diagnosed with congestive heart failure, started on medical therapy, and chose outpatient follow-up for the cyst without further intervention. **Discussion:** The coexistence of dextrocardia and an arachnoid cyst suggests a potential genetic link and supports comprehensive genetic evaluation in patients with congenital anomalies. Recognizing such associations may improve understanding of underlying developmental mechanisms and help refine diagnostic and management strategies.

**Keywords:** dextrocardia, arachnoid cyst, genetics, case report

<sup>1</sup>Department of Cardiology and Vascular Medicine, Faculty Medicine, Gorontalo State University, Indonesia

<sup>2</sup>Aloei Saboe General Hospital Gorontalo, Indonesia

<sup>3</sup>Department of Neurology, Faculty Medicine, Gorontalo State University, Indonesia

<sup>4</sup>Department of Pharmacology, Faculty Medicine, Gorontalo State University, Indonesia

**Correspondencia:** Muchtar Nora Ismail Siregar. Department of Cardiology and Vascular Medicine, Faculty Medicine, Gorontalo State University, Indonesia; Aloei Saboe General Hospital Gorontalo, Indonesia

E-mail: noraismailsiregar@ung.ac.id

Recibido: 29/01/2025

Aceptado: 20/03/2025

## Introduction

Congenital heart disease (CHD) refers to structural abnormalities of the heart or blood vessels present at birth and is the most common type of congenital malformation, contributing significantly to morbidity and mortality. Dextrocardia, a rare condition occurring in about 1 in 12,000 births, involves the abnormal positioning of the heart [1]. While the exact cause remains unclear, it is believed to result from disruptions during early cardiac development. Recent studies have pointed to genetic factors, such as copy number variations (CNVs) and specific mutations, which may be linked to isolated dextrocardia and could increase susceptibility to other congenital defects, including arachnoid cysts of the central nervous system [2]. This case highlights an unusual and underexplored association between dextrocardia and an arachnoid cyst in the posterior fossa, a co-occurrence that has not been frequently described in the medical literature.

## Case Presentation

A 25-year-old female presented with a one-year history of exertional dyspnea, orthopnea, and paroxysmal nocturnal dyspnea. She also reported associated generalized fatigue and bilateral peripheral edema. Notably, the patient had no significant medical history, including hypertension, diabetes mellitus, chronic kidney disease, or smoking. Additionally, she experiences frequent headaches. On physical examination, her blood pressure was 100/60 mmHg, heart rate 125 beats per minute, respiratory rate 28 breaths per minute, and jugular venous pressure (JVP) was elevated. Cardiac auscultation revealed regular S1 and S2 heart sounds, with a systolic murmur audible at the 6th intercostal space along the right anterior axillary line. Pulmonary examination revealed vesicular breath sounds with bilateral rhonchi. Examination also revealed ascites and bilateral lower extremity edema.

Laboratory tests revealed mild anemia (hemoglobin 9.0 g/dL), preserved renal function (eGFR 105 mL/min/1.73 m<sup>2</sup>), and normal levels of serum protein, albumin, and globulin. The electrocardiogram findings are depicted in Figure 1. A Chest X-ray showed dextrocardia, cardiomegaly, and signs of pulmonary congestion (Figure 2). Echocardiography showed mildly reduced left ventricular ejection fraction 44%, left atrial enlargement, and moderate mitral regurgitation (Figure 3). A contrast-enhanced brain CT scan identified an arachnoid cyst

in the posterior fossa (Figure 4).

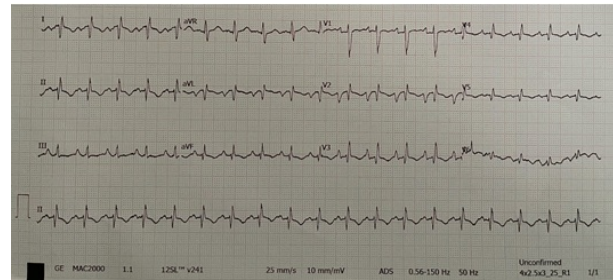


Figure 1: The electrocardiogram at presentation revealed global negativity in lead I, positive QRS with upright p wave and T wave in lead aVR, and absent R wave progression in precordial lead

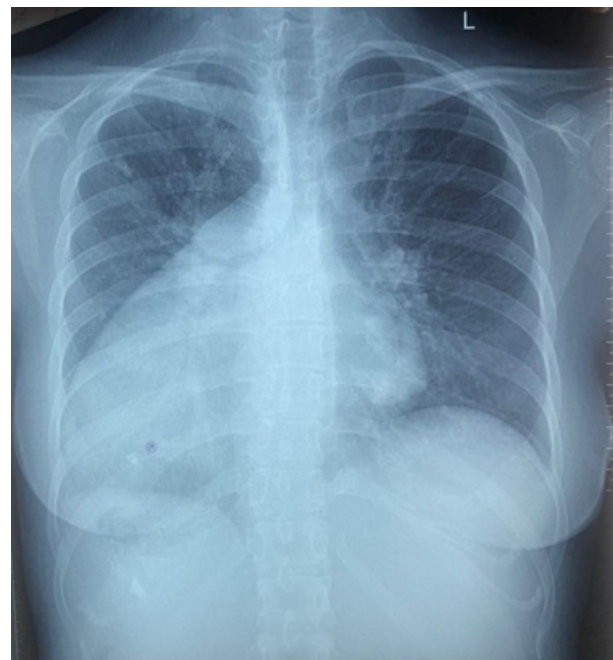


Figure 2: Chest X-ray showed dextrocardia with cardiomegaly, sign of pulmonary congestion

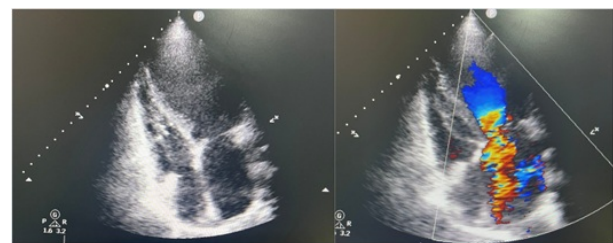


Figure 3: Echocardiography demonstrated moderate mitral regurgitation and left atrial enlargement

The patient was diagnosed with congestive heart failure with mildly reduced ejection fraction, dextrocardia, mitral regurgitation, arachnoid cyst and initi-

ated intravenous diuretics with furosemide 120 milligrams per day, angiotensin-converting enzyme inhibitors, mineralocorticoid receptor antagonists, and beta-blockers. Although she was counseled regarding the management of the posterior fossa arachnoid cyst, the patient opted against further intervention. The patient underwent treatment for a duration of 5 days while maintaining stable hemodynamic conditions. She was subsequently discharged with instructions for routine follow-up in the outpatient clinic.

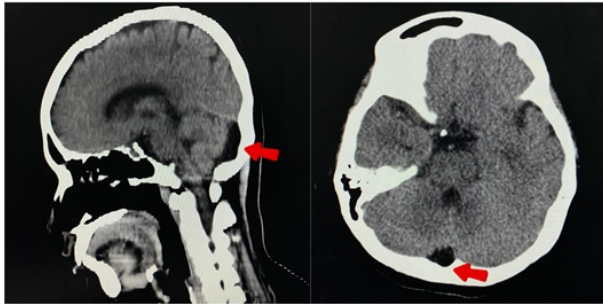


Figure 4: Contrast-enhanced brain CT scan identified an arachnoid cyst in the posterior fossa

### Discussion

This case is the first to document an unusual and underreported connection between dextrocardia and a posterior fossa arachnoid cyst, a co-occurrence infrequently reported in the literature. Although both dextrocardia and arachnoid cysts are rare on their own, their concurrent development in an otherwise young patient poses intriguing questions about possible embryologic and genetic relationships that might give rise to these malformations. Since both conditions are developmental processes that occur early in fetal life, the potential for common genetic or developmental mechanisms should be explored.

#### Dextrocardia: A Genetic and Developmental Perspective

Genetically, dextrocardia can be caused by disruptions in the left-right asymmetry signaling pathway during embryogenesis. The most important molecular pathways implicated in this process are sonic hedgehog (SHH), *lefty-1*, and nodal pathways, which are essential for the determination of normal leftward rotation and asymmetrical development of internal organs. Mutations in these gene or the pathway they control can result in situs anomalies, such as dextrocardia. In addition, dysfunction of cilia has been associated with dextrocardia in conditions like primary ciliary dyskinesia and Kartagener syndrome, both of

which involve defective ciliary movement that compromises normal rotation of the organs during embryogenesis [2, 3]. Notably, investigation into the genetic etiology of situs anomalies continues, and recent evidence indicates that copy number variations (CNVs) and certain genetic mutations may play a role in isolated dextrocardia, potentially conferring increased susceptibility to other malformations, such as those of the central nervous system (CNS), such as arachnoid cysts.

#### Arachnoid Cysts in the Posterior Fossa: Genetic Underpinnings

Arachnoid cysts (ACs) are collections of cerebrospinal fluid (CSF) in the central nervous system lined with thin arachnoid membranes contiguous with normal adjacent arachnoid containing hyperplastic arachnoid cells, excess collagen, and absence of normal spider-like trabeculations. The majority of AC patients are found to be asymptomatic, with 5%–12% of AC patients being symptomatic [4]. The precise etiology of arachnoid cysts is not entirely clear, but they are believed to be due to splitting or resorption failure of the arachnoid membrane during early brain development. Though the majority of arachnoid cysts are sporadic, certain IACs are believed to be secondary to gestational ischemic, traumatic, or infectious insult [5]. Experiments have shown correlations with a number of genetic syndromes involving arachnoid cysts, such as Ehlers-Danlos syndrome, Marfan syndrome, and neurofibromatosis type 1, all with underlying connective tissue defects and tissue development abnormalities. In addition, mutations in structural protein components that impair the integrity of the arachnoid layer of the brain or interruption of neurogenetic pathways may render individuals susceptible to cyst formation [6].

An enhanced prevalence of ACs has been reported in various syndromes hitherto. The occurrence of arachnoid cysts in patients with other congenital malformations is suggestive of a potential syndromic association, with partial evidence favoring common genetic pathways between CNS malformations and organ laterality defects. For instance, primary ciliary dyskinesia (PCD), a disorder well-documented to lead to dextrocardia, has been linked with cystic cerebral lesions, including arachnoid cysts, in a few instances [7]. This provokes the speculation that a common genetic defect in left-right patterning or cilia function might underlie the association between the two, both dextrocardia and arachnoid cysts.

## Clinical Implications and Future Research

The possible genetic correlation between dextrocardia and arachnoid cysts makes it all the more critical that patients with congenital anomalies undergo thorough genetic assessment. Although both are likely to be asymptomatic, together they may represent part of an underlying developmental syndrome that should be investigated. The identification of overlapping genetic pathways not only might enhance our knowledge of these conditions but also might inform clinical management, especially in those who also have other associated congenital anomalies.

There will need to be further investigation into the genetic causes of dextrocardia and arachnoid cysts to determine possible connections as well as to discover the particular mutations or pathways that are responsible for their development. Further, the use of genomic sequencing in uncovering rare mutations would assist in developing a more accurate explanation of the genetic factors involved in the concomitant occurrence of these two diseases.

## Conclusion

This case of a 25-year-old female with dextrocardia and an incidental posterior fossa arachnoid cyst presents an intriguing clinical scenario that may suggest a potential genetic or embryological connection. Although direct evidence linking dextrocardia with arachnoid cysts is limited, the possibility of shared genetic defects affecting left-right asymmetry and CNS development warrants further investigation. Understanding the genetic basis of these conditions could provide valuable insights into their pathophysiology, aid in diagnosis, and guide management strategies in affected individuals.

## Data availability

The data underlying this article will be shared on reasonable request to the corresponding author.

## Abbreviations

eGFR: estimated Glomerular Filtration Rate  
CT scan: Computerized Tomography  
CNVs: Copy Number Variations  
CNS: Central Nervous System  
ACs: Arachnoid Cyst  
CFS: Cerebrospinal Fluid  
PCD: Primary Ciliary Dyskinesia

## Competing interests

The authors declare that they have no competing interests.

## Authors' Contributions

Muchtar Nora Ismail Siregar, as the lead author, conducted the medical screening, designed the study, and drafted the manuscript. Vickry H. Wahidji contributed to patient review and investigation. Muhammad Isman Jusuf participated in patient review and investigation, as well as manuscript review and editing. Zuhriana K. Yusuf made substantial contributions to the conception and design of the study and was involved in reviewing and editing the manuscript.

## Acknowledgements

The authors would like to thank all the staff of the Department of Cardiology and Vascular Medicine, Gorontalo State University, for their support

## Consent

Written informed consent was obtained from the patient for publication of this case report and any accompanying images. A copy of the written consent is available for review by the Editor-in-Chief of this journal.

## Referencias bibliográficas

- [1] Bohun, Claudine M., et al. "A population-based study of cardiac malformations and outcomes associated with dextrocardia." *The American Journal of Cardiology* 100.2 (2007): 305-309.
- [2] Pierpont, Mary Ella, et al. "Genetic basis for congenital heart disease: revisited: a scientific statement from the American Heart Association." *Circulation* 138.21 (2018): e653-e711.
- [3] Eitler, Katalin, András Bibok, and Gábor Telkes. "Situs inversus totalis: a clinical review." *International Journal of General Medicine* (2022): 2437-2449.
- [4] Hall, Samuel, et al. "Natural history of intracranial arachnoid cysts." *World Neurosurgery* 126 (2019): e1315-e1320.
- [5] Jafrani, Ryan, et al. "Intracranial arachnoid cysts: Pediatric neurosurgery update." *Surgical Neurology International* 10 (2019): 15.
- [6] Qureshi, Hanya M., et al. "Familial and syndromic forms of arachnoid cyst implicate genetic factors in disease pathogenesis." *Cerebral Cortex* 33.6 (2023): 3012-3025.

[7] Robson, Evie Alexandra, et al. "Hydrocephalus and diffuse choroid plexus hyperplasia in primary ciliary

dyskinesia-related MCIDAS mutation." *Neurology: Genetics* 6.4 (2020): e482.